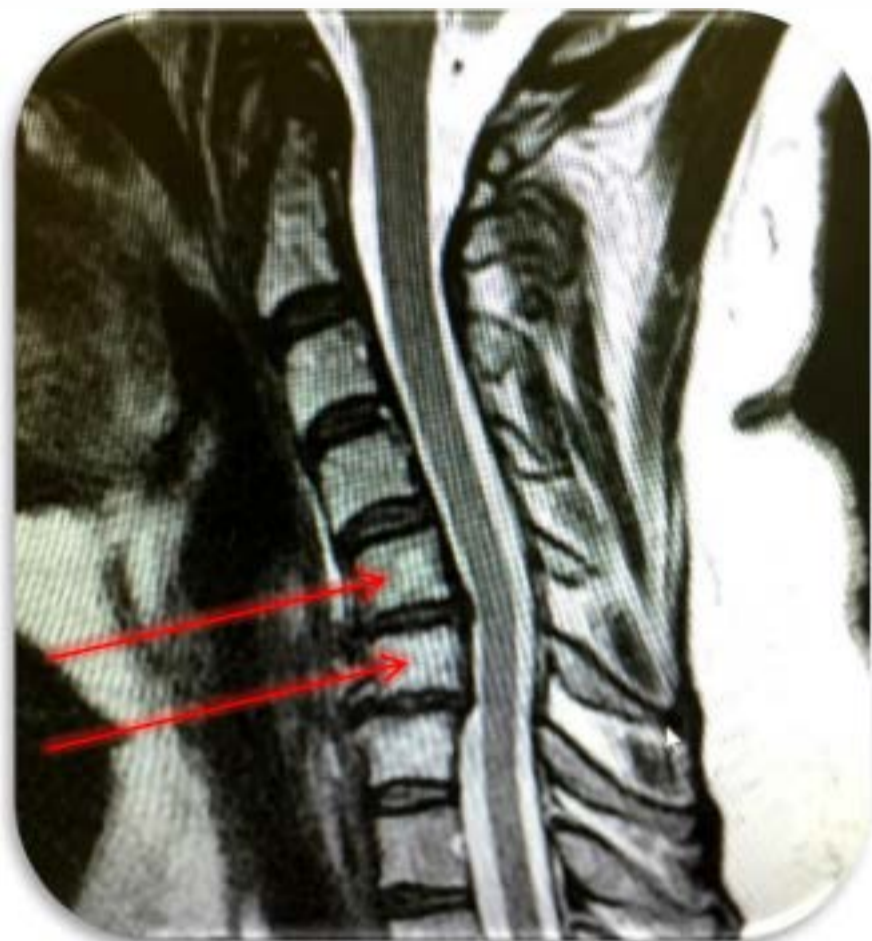
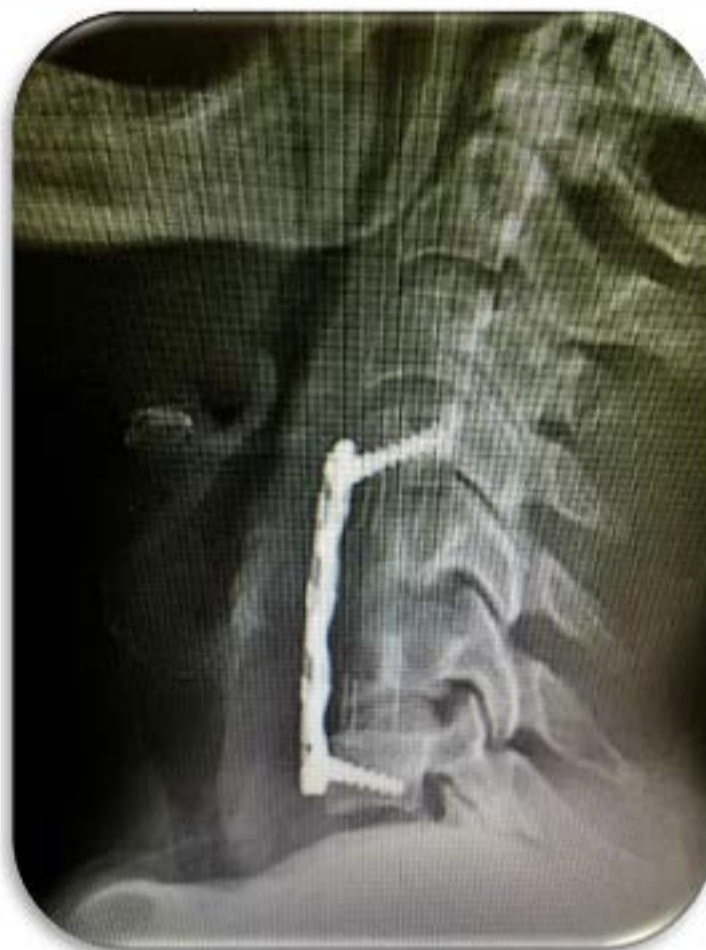
Hensler Bone Press – Case Presentation

ANTERIOR Cervical Corpectomy C5 and C6, Interbody Strut C4-7 with Anterior Plate C4-7



Pre-OP Film



Post-OP Film

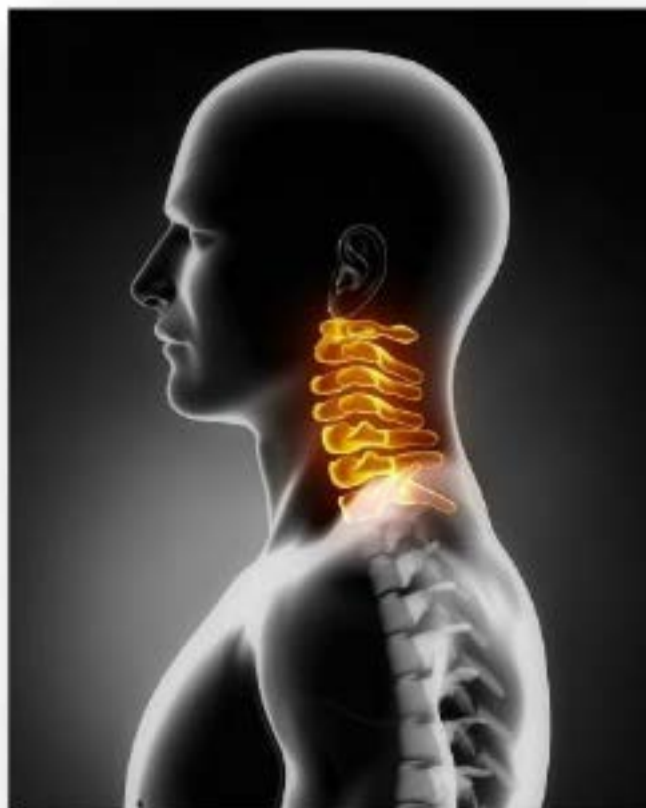Anterior Corpectomy C5 and C6.

48 y/o female with severe cervical stenosis
and reversal of Kyphosis.

Autograft harvested via the high speed drill
using the HBP.

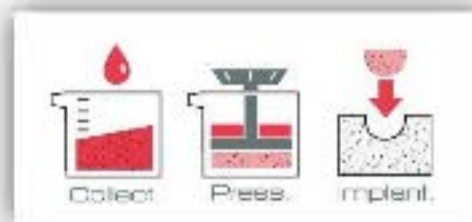
Interbody Strut packed
tight with AUTOGRAFT
from the Hensler Bone
Press.

(Anterior plate/Strut Medtronic®
Hardware shown above.)



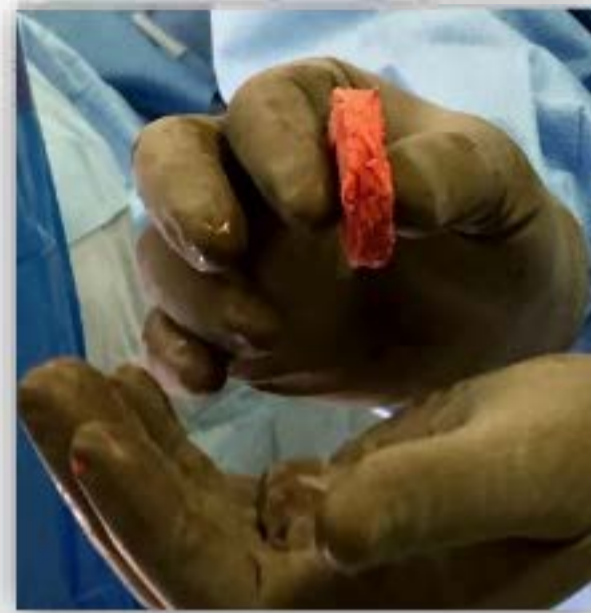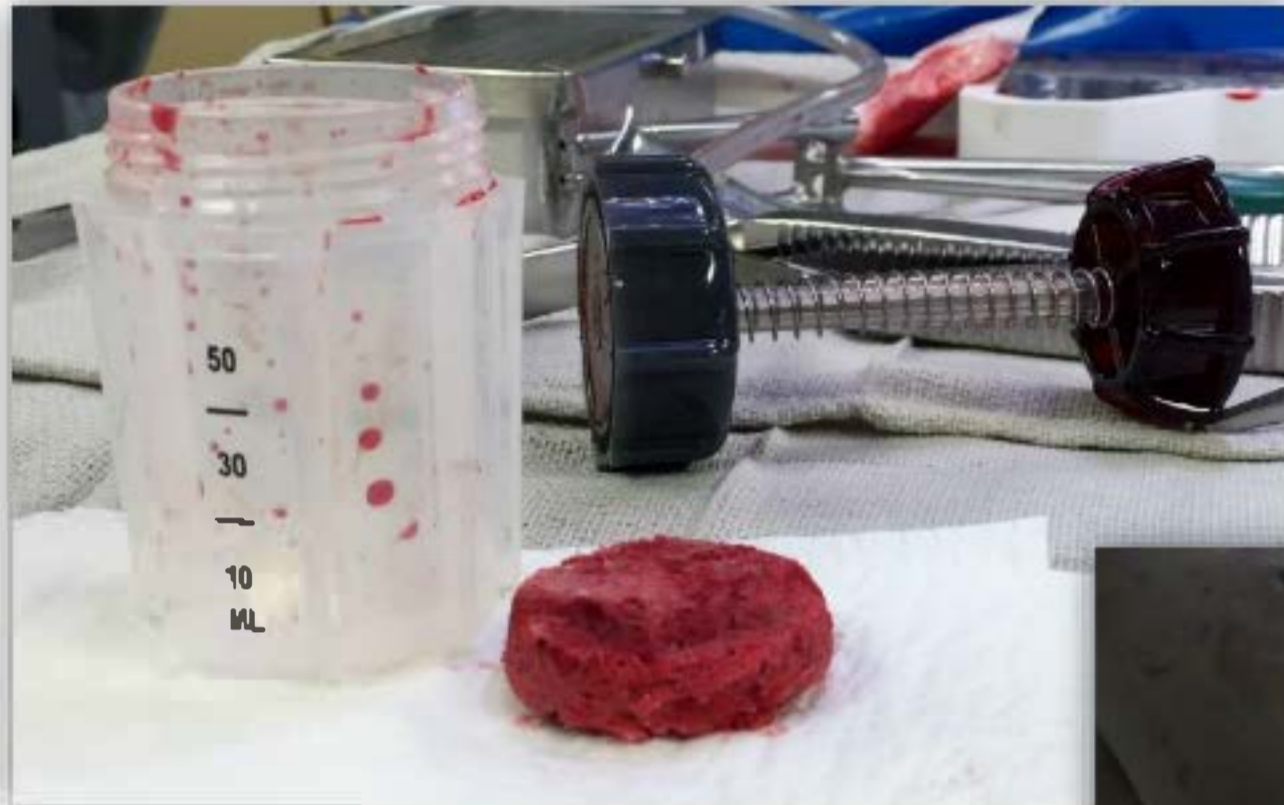Value Proposition using the HBP in this case ..

- ~20 cc HBP graft (Autologous graft only used.)
 - I. > \$ 2,000 savings (Synthetics / DBM)
 - II. Used graft for interbody strut graft. (42.5 mm).
 - III. Less time to process (OR time saved)
 - IV. After interbody placed within interbody strut, extra bone was approximately 8-9 cc.



Hensler Bone Press - Case Presentation

ANTERIOR Cervical Corpectomy C5 and C6 Interbody Strut C4/7 with Anterior Plate C4/7



This is what is saved
by using
AUTOGRAFT
harvested from the
HBP.

This was LEFT OVER
bone AFTER the
strut was packed.

