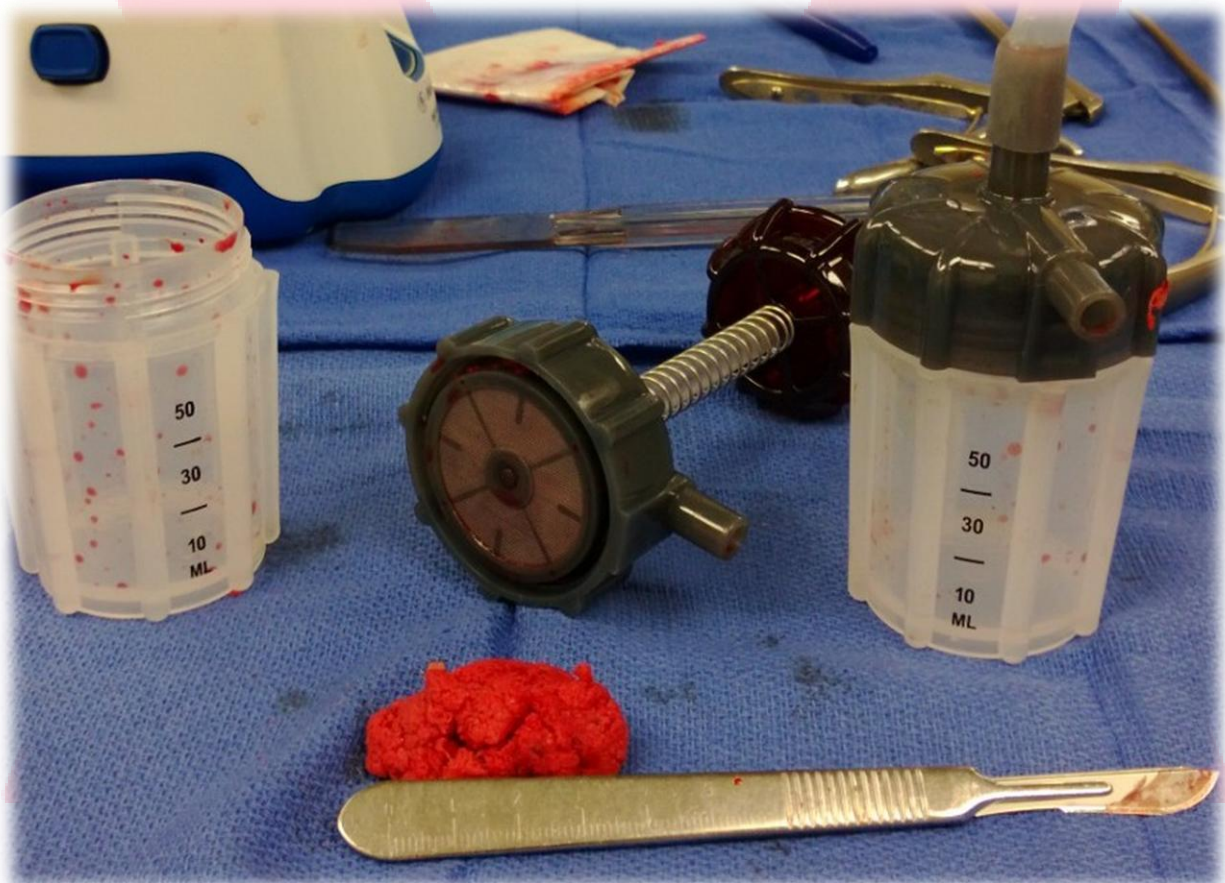


HENSLER X SURGICAL PRODUCTS™

Decompressive (Narrow) Lumbar Laminectomy L4/5 with Posterolateral Fusion

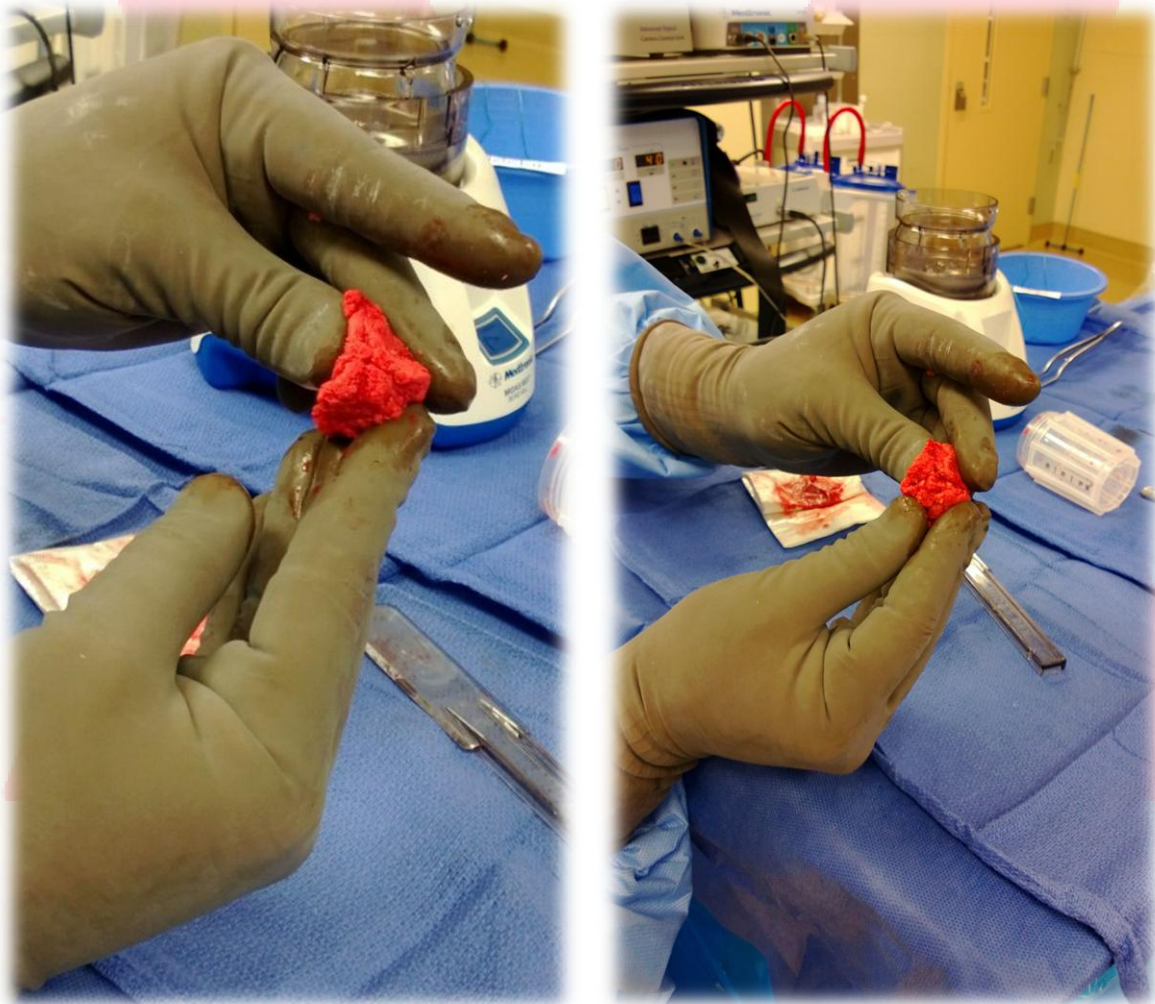


Points of Interest:

- After 2-3 presses and evacuating the blood, the bone was placed onto a Telfa pad.
- The bone collected was augmented with < 5cc synthetic to fill the posterolateral gutters.
- We collected over 7-8 cc Autologous bone. (Lamina, Lower spinous process, Decortication)
- No facet complex was drilled or collected.

HENSLELER SURGICAL P R O D U C T S™

Decompressive (Narrow) Lumbar Laminectomy L4/5 with Posterolateral Fusion



Points of Interest:

- As you can see, the bone was very favorable and malleable with excellent texture.